



KLINISCHE BEFUNDE
CLINICAL RESULTS



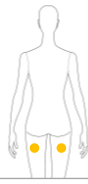TERMO SALUD
MEDICAL
& AESTHETIC

Beispiel A

Frau, 47 Jahre alt

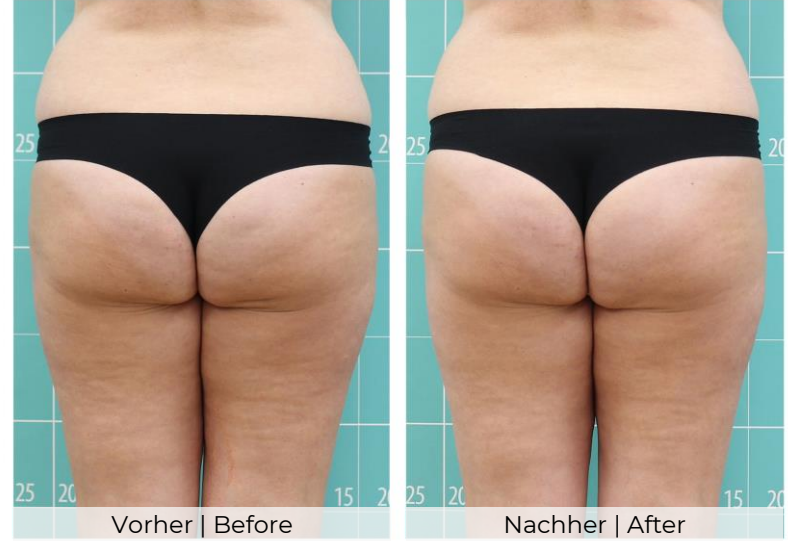
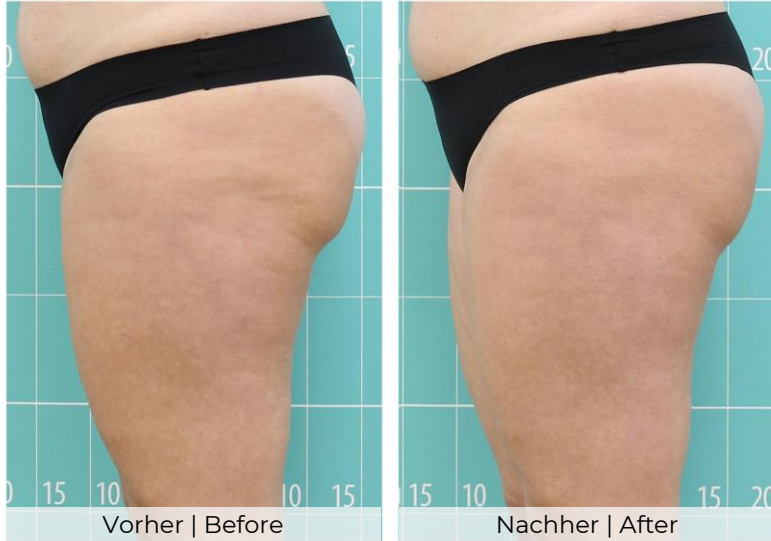Case A

Woman, 47 years old



Behandlung zur Verringerung der Fettleibigkeit an den Oberschenkeln
Adiposity reduction treatment on the thighs

Adiposität-Transmitter
Antiadiposity transmitter



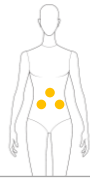
8 Vmat PRO Sitzungen | 8 sessions of Vmat PRO

Beispiel B

Frau, 45 Jahre alt

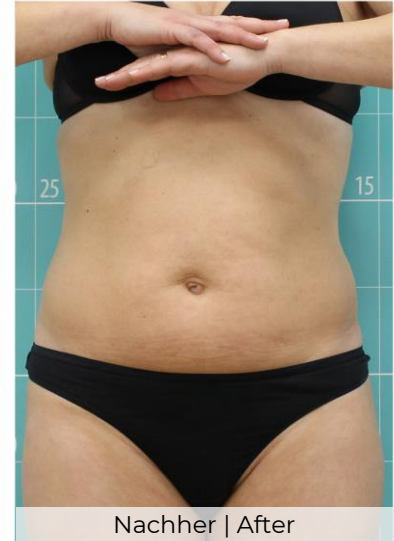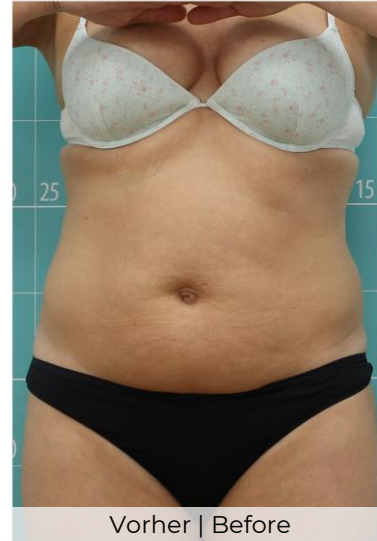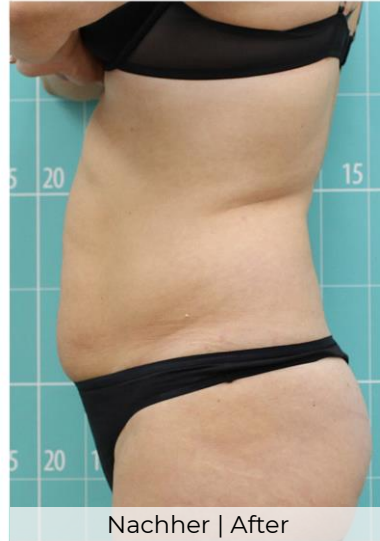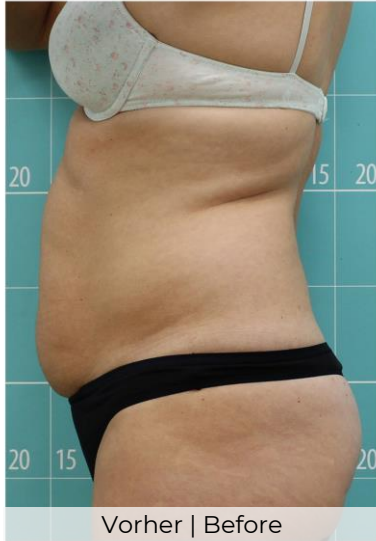Case B

Woman, 45 years old



Behandlung zur Verringerung der Fettleibigkeit an den Bauchbereich
Adiposity reduction treatment on the abdomen

Adiposität-Transmitter
Antiadiposity transmitter



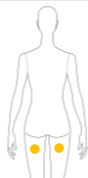8 Vmat PRO Sitzungen | 8 sessions of Vmat PRO

Beispiel C

Frau, 44 Jahre alt

Case C

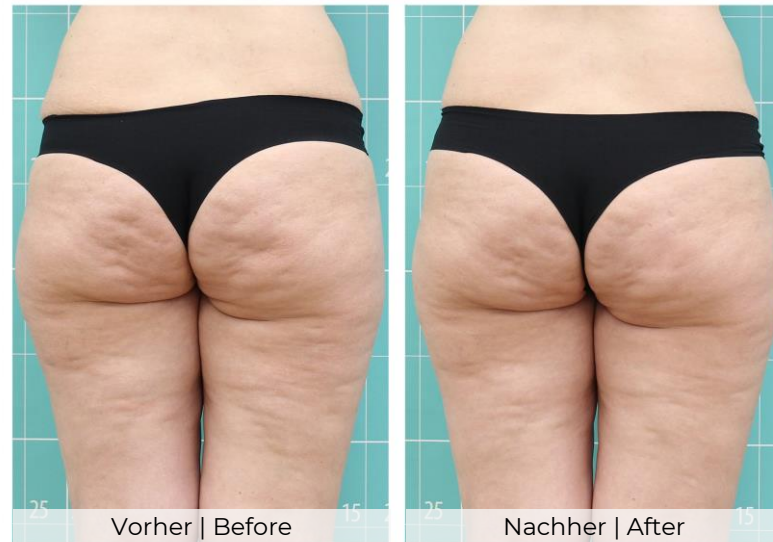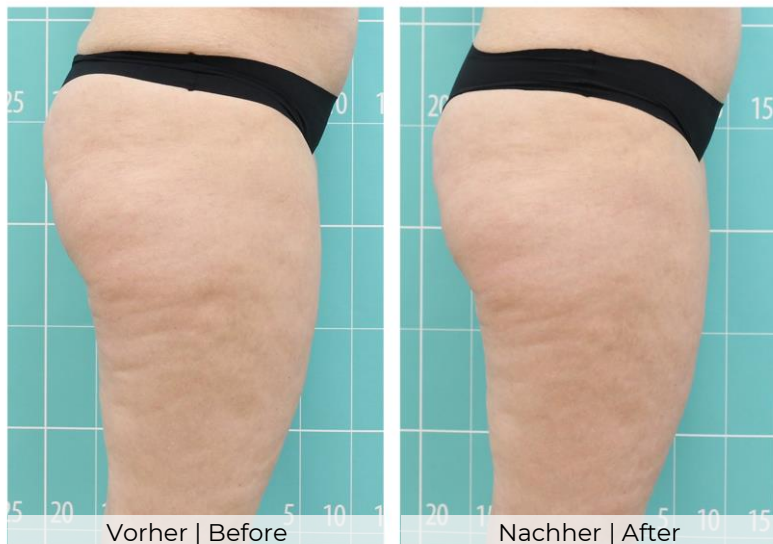Woman, 44 years old



Cellulite-Behandlung

Cellulite reduction

Anticellulite Transmitter
Anti - cellulite transmitter



8 Vmat PRO Sitzungen | 8 sessions of Vmat PRO

Beispiel D

Frau, 40 Jahre alt

Case D

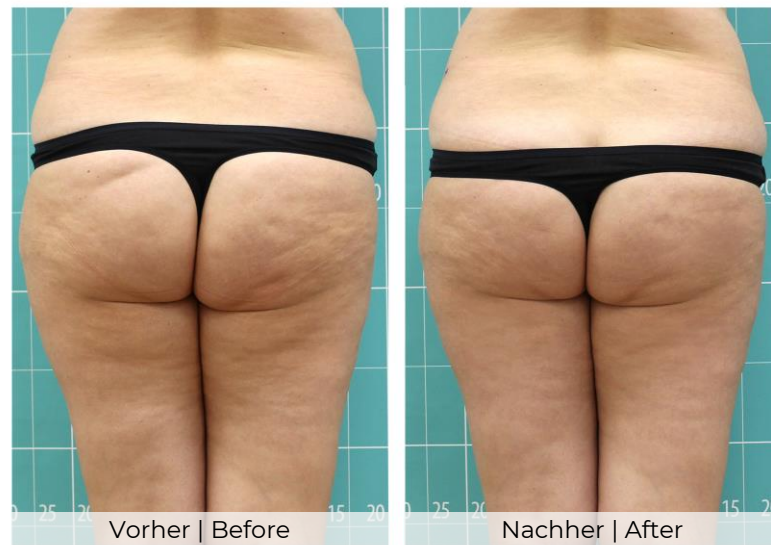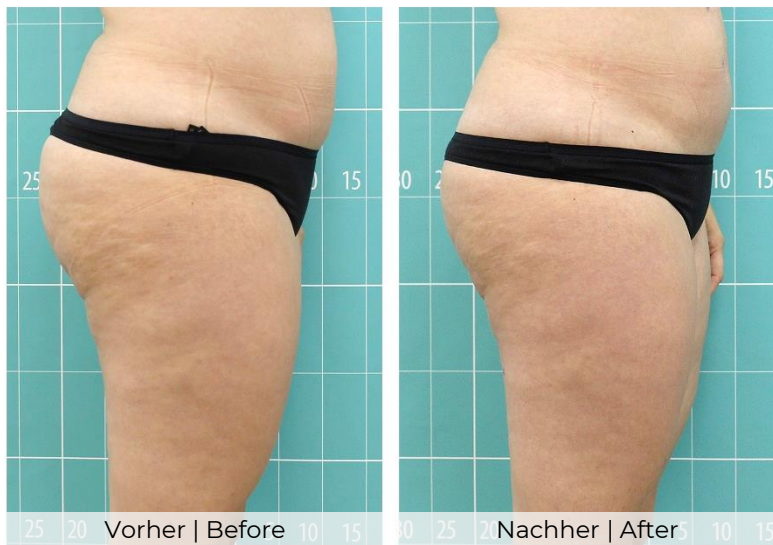Woman, 40 years old



Cellulite-Behandlung

Cellulite reduction

Anticellulite Transmitter
Anti - cellulite transmitter



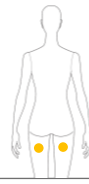8 Vmat PRO Sitzungen | 8 sessions of Vmat PRO

Beispiel E

Frau, 39 Jahre alt

Case E

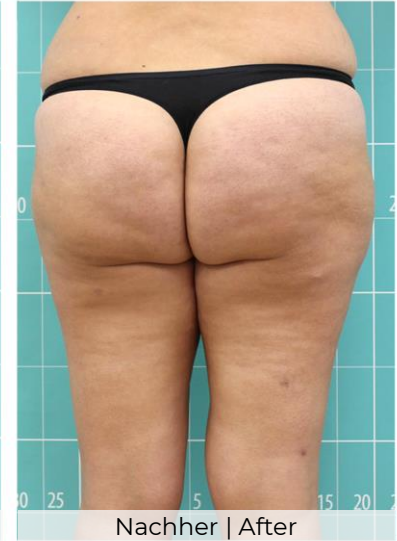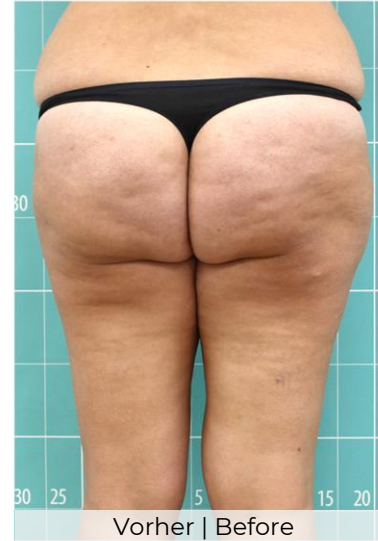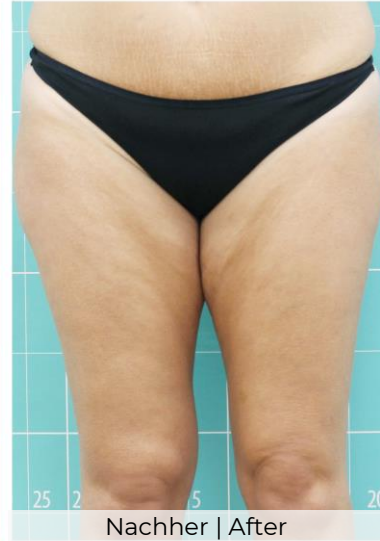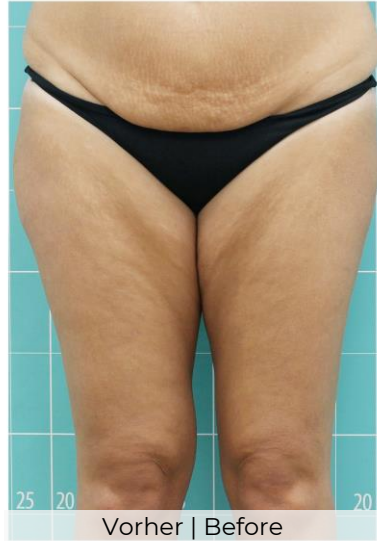Woman, 39 years old



Cellulite-Behandlung

Cellulite reduction

Anticellulite Transmitter
Anti - cellulite transmitter



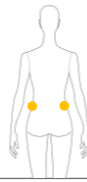
8 Vmat PRO Sitzungen | 8 sessions of Vmat PRO

Beispiel F

Mann, 33 Jahre alt

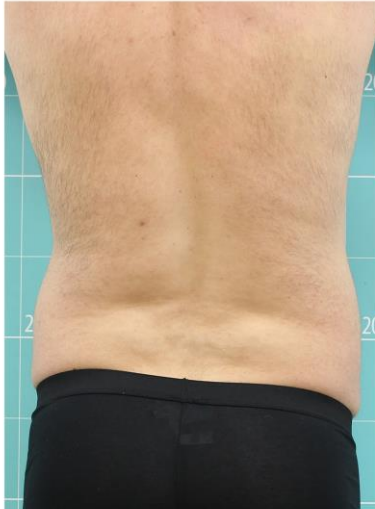Case F

Man, 33 years old

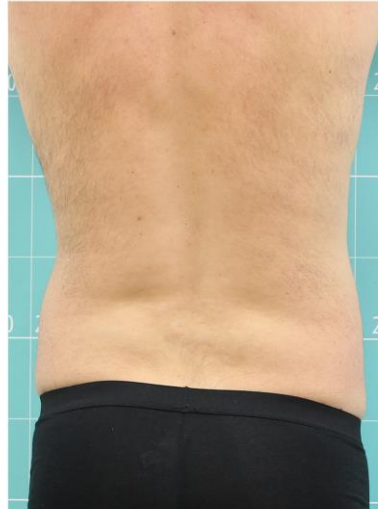

Behandlung zur Reduzierung der Flankenfettleibigkeit
Flanks adiposity reduction treatment

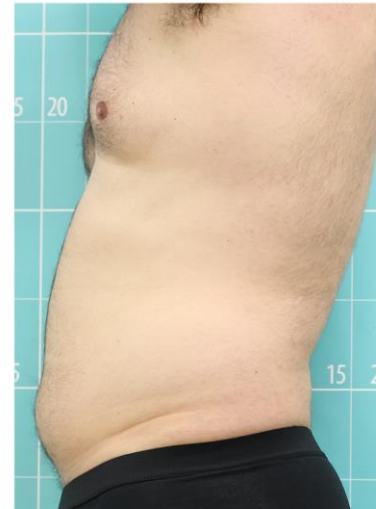Adiposität-Transmitter
Antiadiposity transmitter



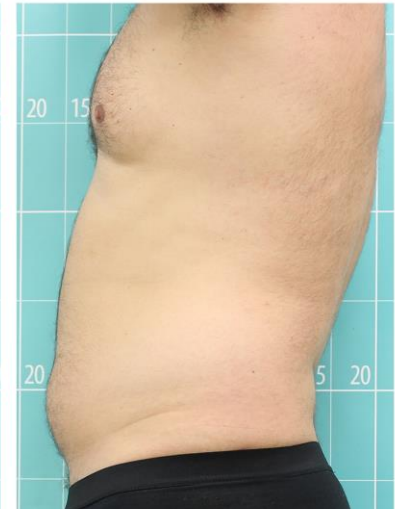Vorher | Before



Nachher | After



Vorher | Before



Nachher | After

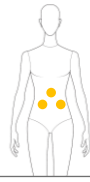
8 Vmat PRO Sitzungen | 8 sessions of Vmat PRO

Beispiel G

Mann, 63 Jahre alt

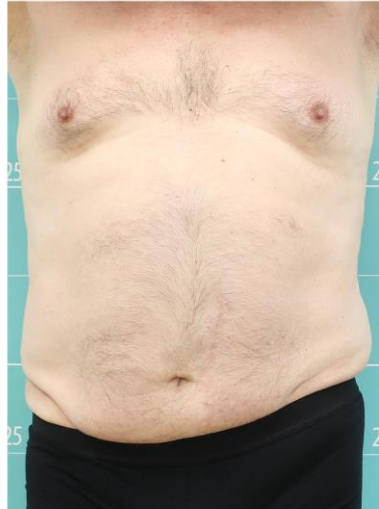Case G

Man, 63 years old

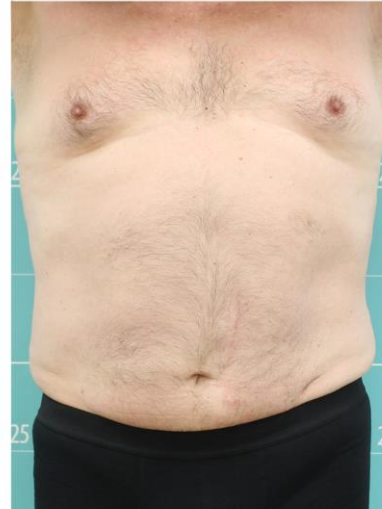

Behandlung zur Verringerung der Fettleibigkeit an den Bauchbereich
Adiposity reduction treatment on the abdomen

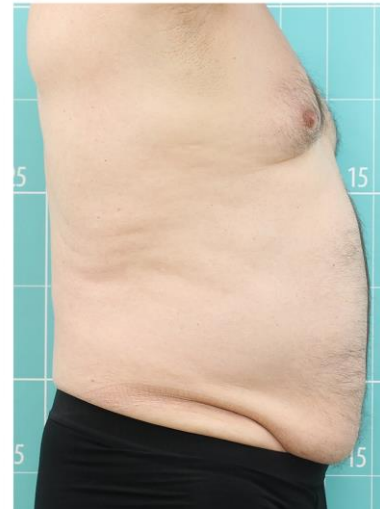Adiposität-Transmitter
Antiadiposity transmitter



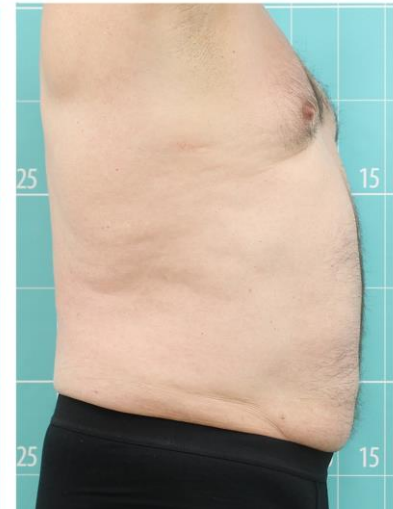Vorher | Before



Nachher | After



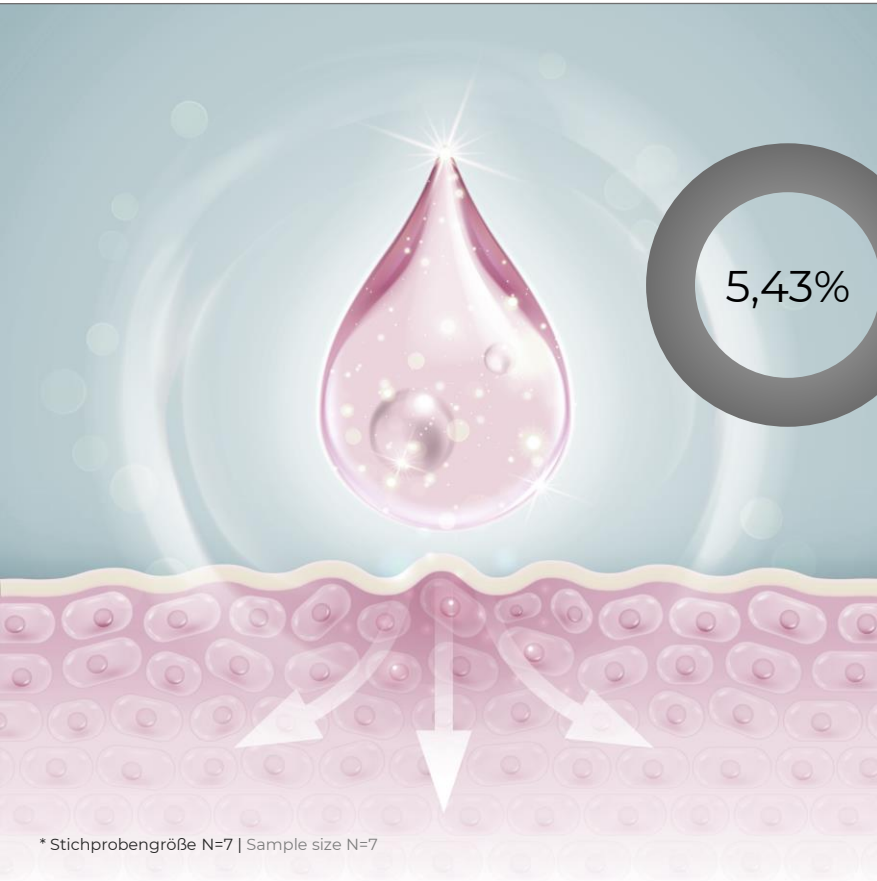
Vorher | Before



Nachher | After

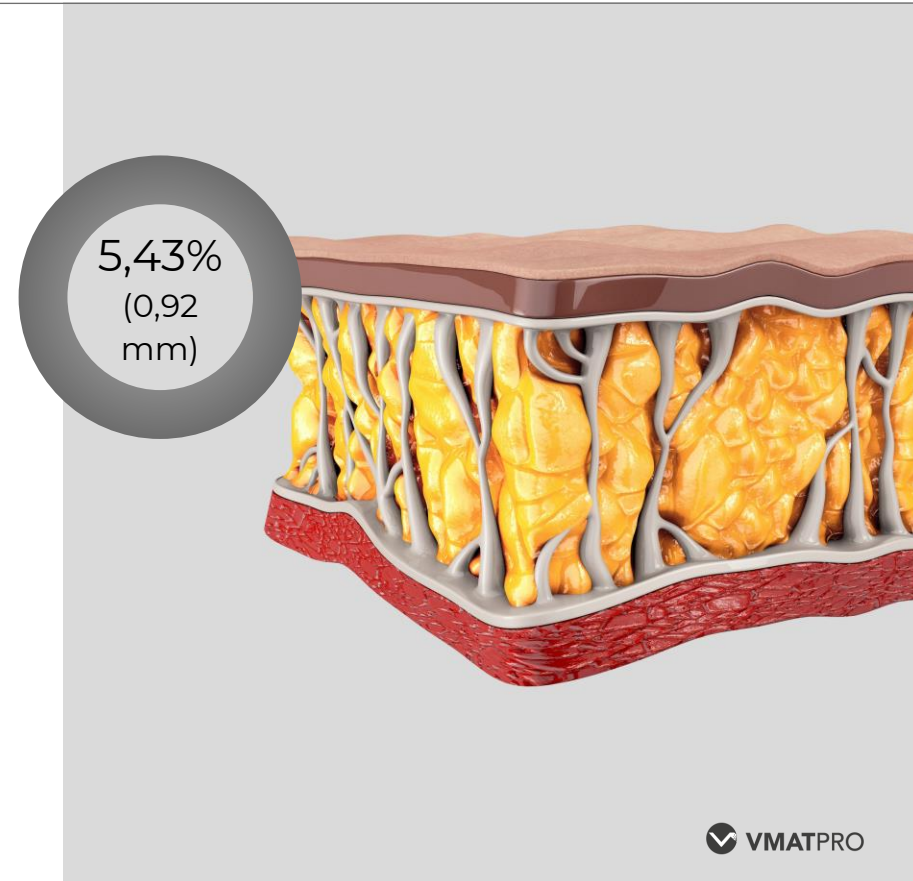
8 Vmat PRO Sitzungen | 8 sessions of Vmat PRO

Verbesserter Kollagenspiegel
Collagen level improvement



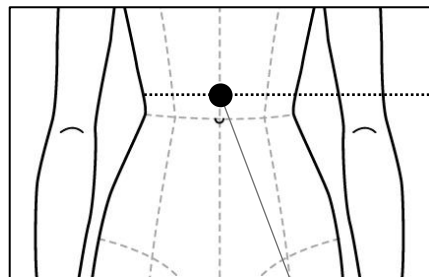
* Stichprobengröße N=7 | Sample size N=7

Reduzierung der Fettschichtdicke
Fat layer thickness reduction

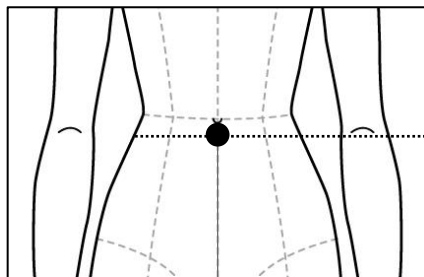
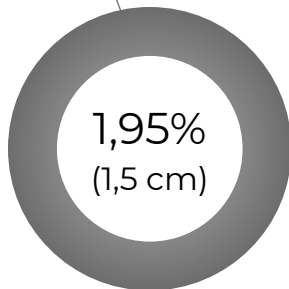


Durchschnittliche Reduktion der Körperkontur | Bauch

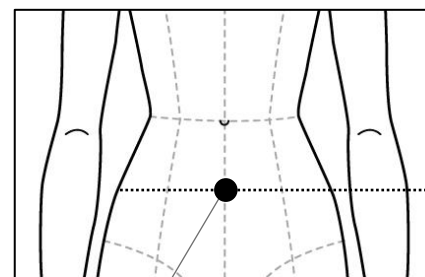
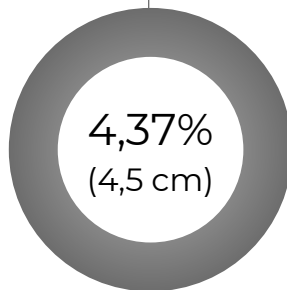
Average body contour reduction | Abdomen



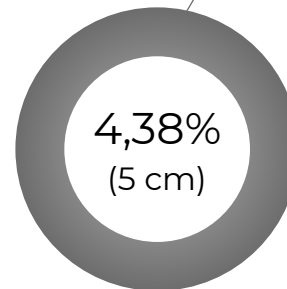
Obere Kontur
Upper contour



Mittlere Kontur
Middle contour

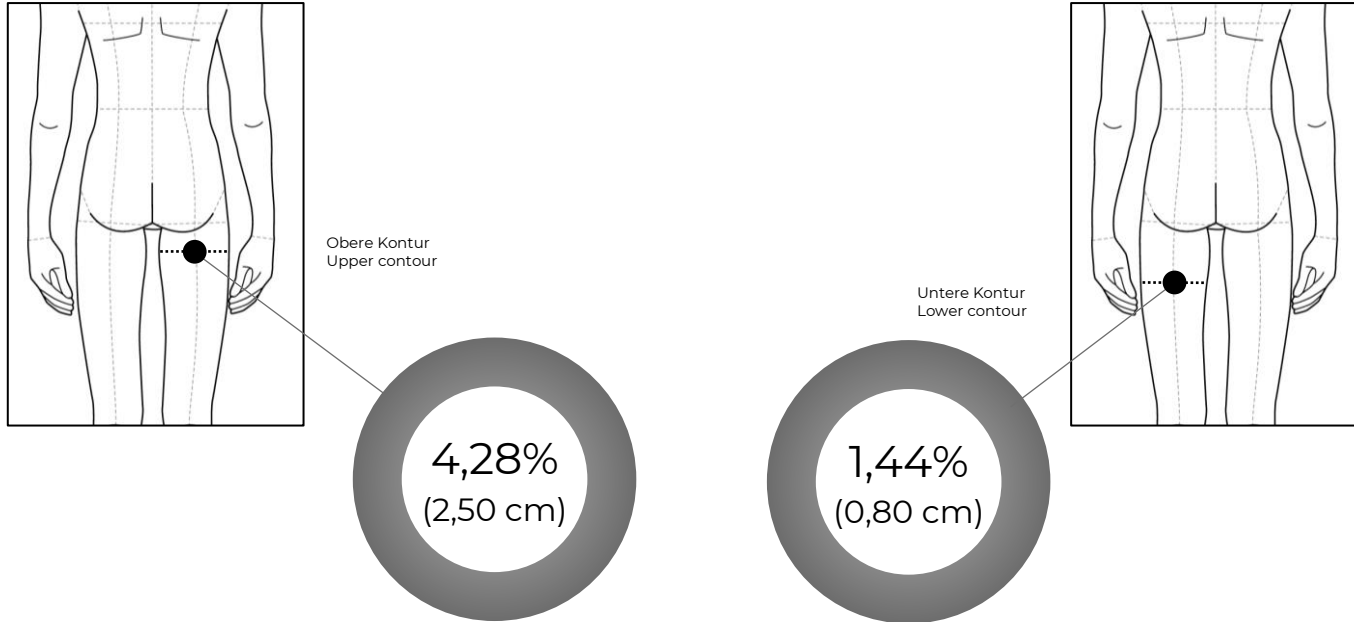


Untere Kontur
Lower contour

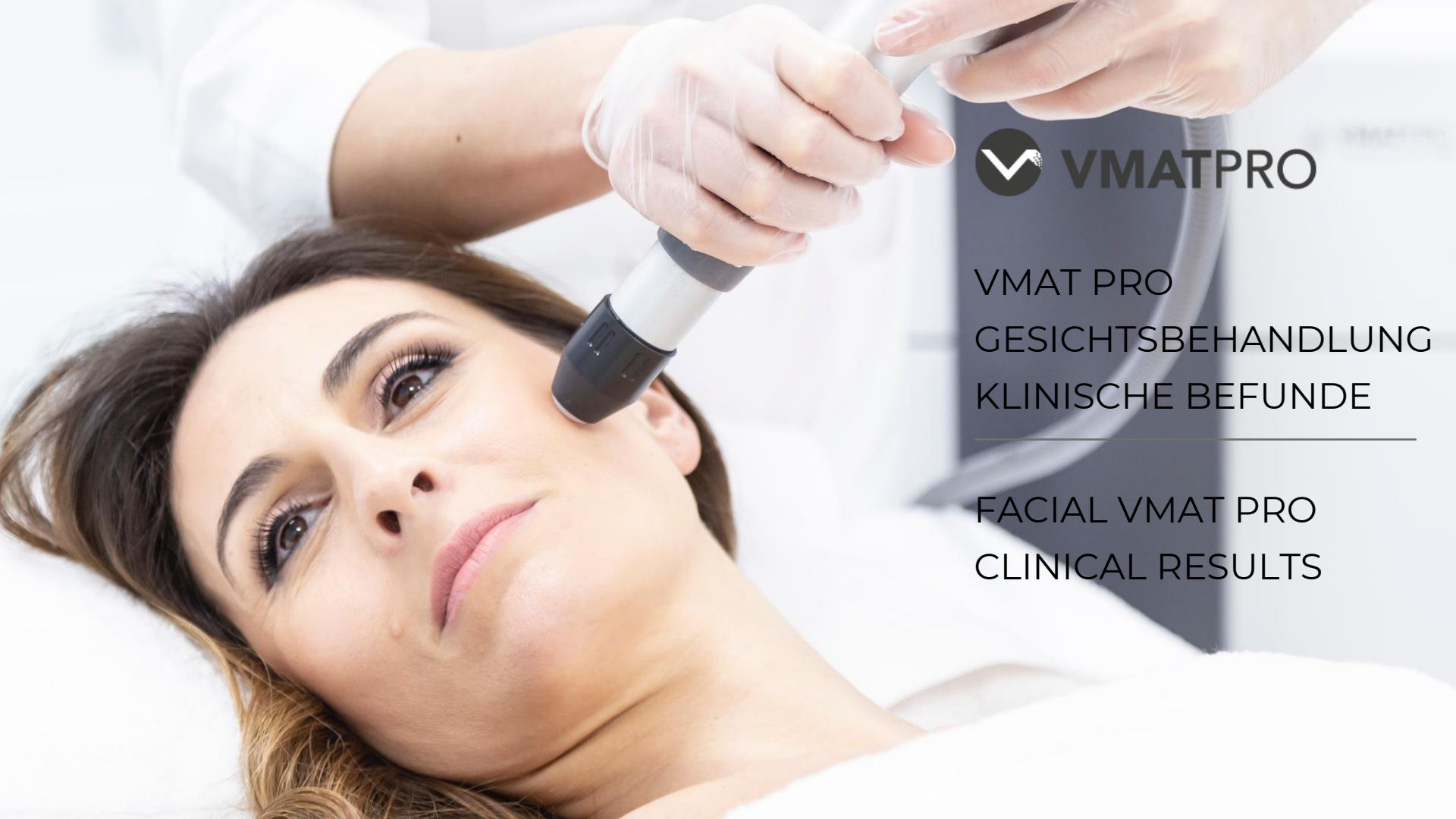

Durchschnittliche Reduktion der Körperkontur | Oberschenkel

Average body contour reduction | Thighs



* Stichprobengröße N=5 | Sample size N=5



VMATPRO

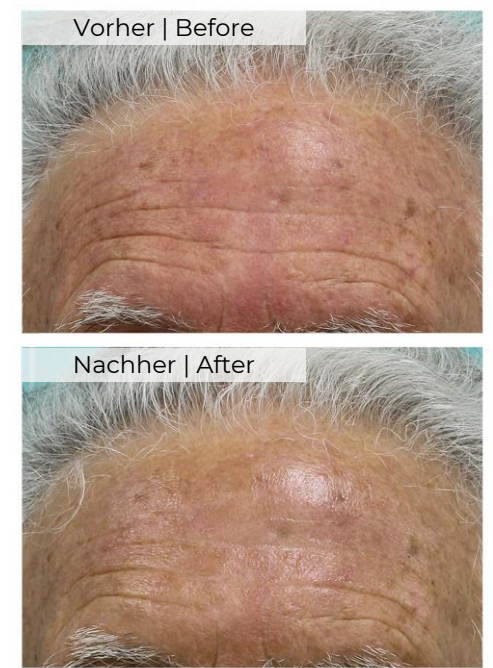
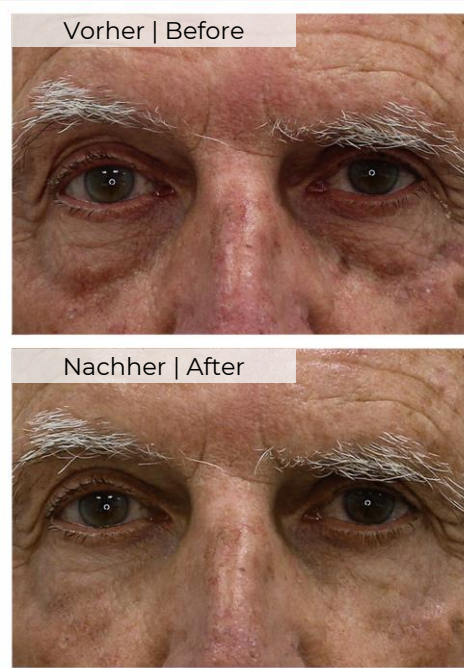VMAT PRO

GESICHTSBEHANDLUNG

KLINISCHE BEFUNDE

FACIAL VMAT PRO

CLINICAL RESULTS



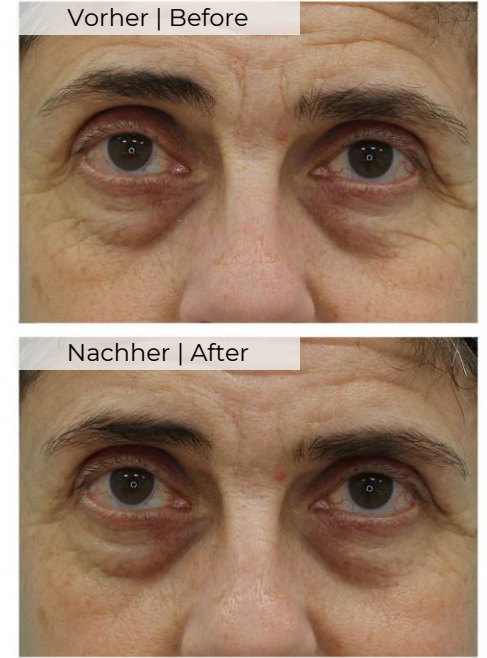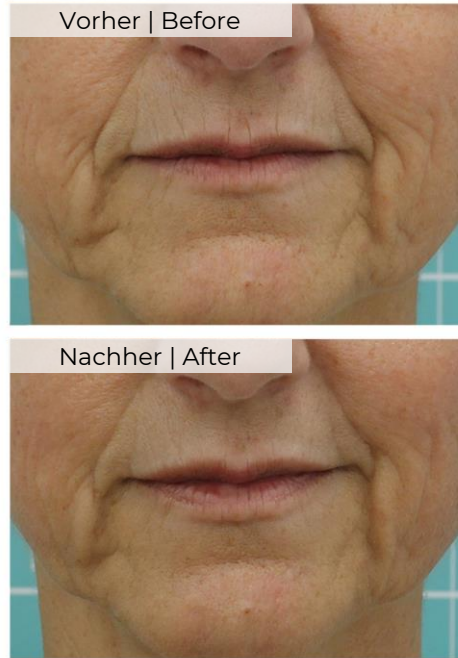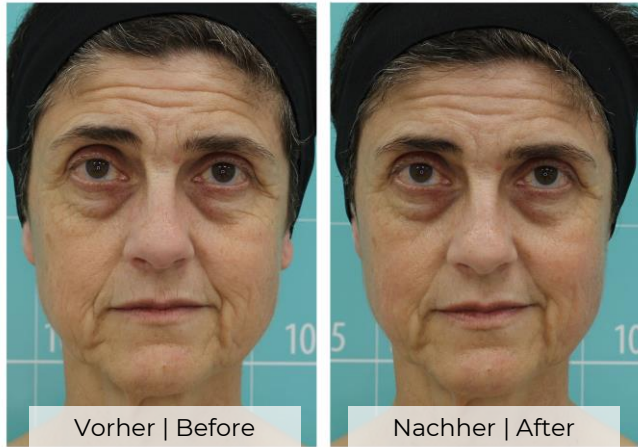Beispiel H

Antiaging-Behandlung
Frau. 56 Jahre alt

Case H

Antiaging treatment
Woman. 56 years old

Antiaging Transmitter
Anti-aging transmitter



1 Vmat PRO Gesichtsbehandlung | 1 session of facial Vmat PRO

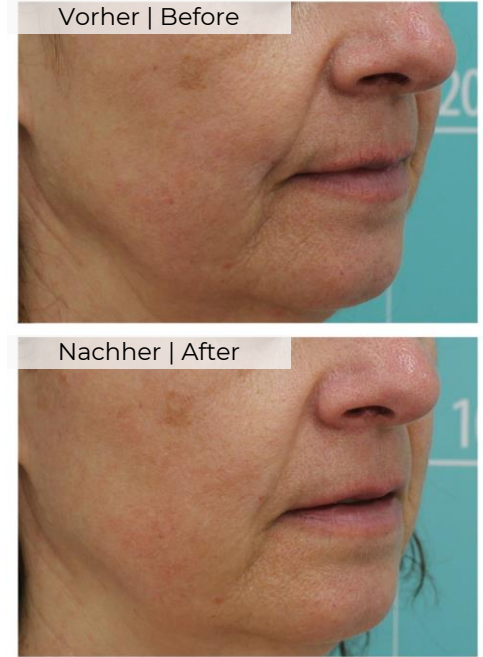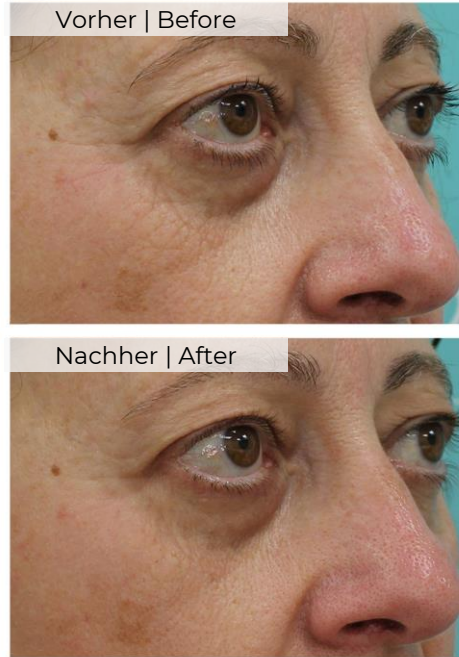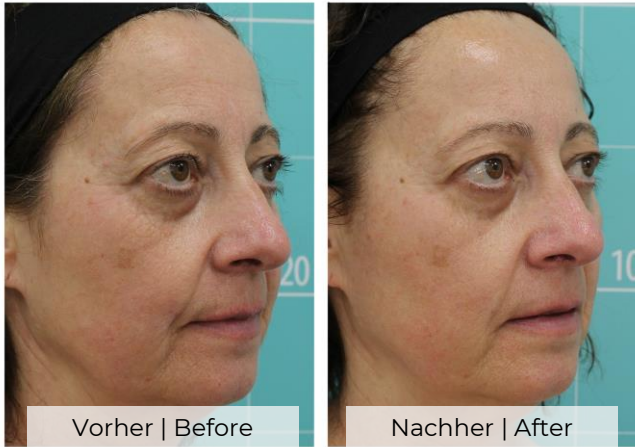Beispiel I

Antiaging-Behandlung
Frau. 58 Jahre alt

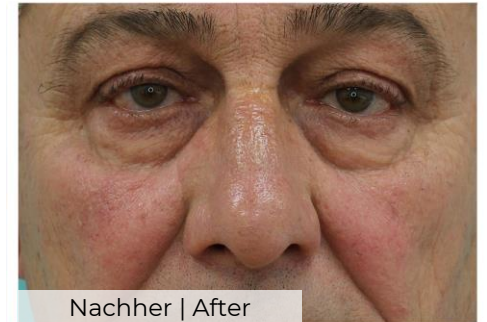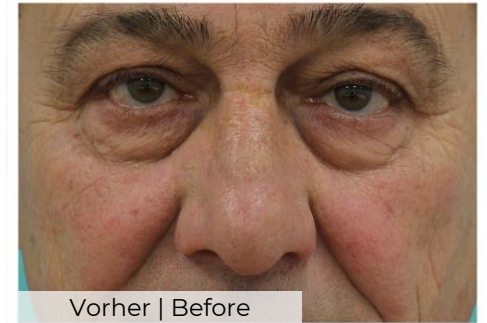

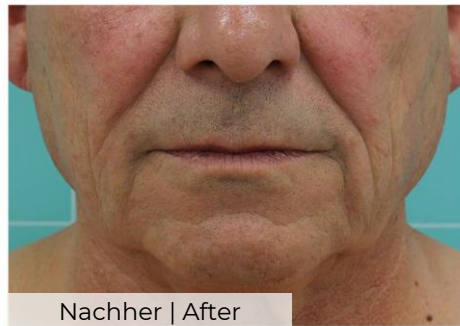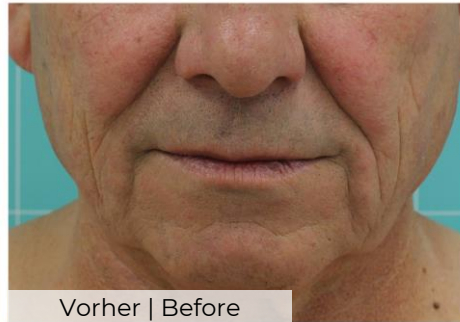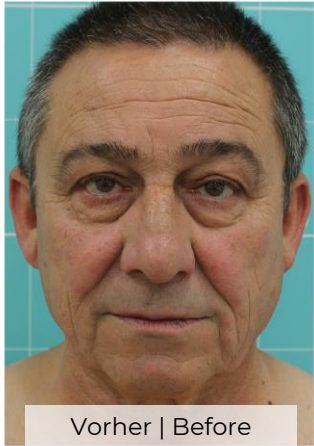Case I


Antiaging treatment
Woman. 58 years old

Antiaging Transmitter
Anti-aging transmitter



6 Vmat PRO Gesichtsbehandlungen | 6 session of facial Vmat PRO





TERMOSALUD

MEDICAL
& AESTHETIC

termosalud.com



certificaste
0199.2018



TERMOSALUD S.L.

P. Ind. Los Campones

c/ Ataúlfo Frieria Tarfe 8

33211 Gijón, Asturias, SPAIN

+34 985 167 547

info@termosalud.com



Acosmed GmbH

Medizinische Geräte für die apparative Kosmetik

Am Beermannshaus 16 | 45549 Sprockhövel

+49 2339 911 911 | info@acosmed.de



Acosmed Medical Aesthetic Academy

Mittelstraße 62a | 40721 Hilden